

Penile fracture in a Peyronie disease - turnitin

by Khoirul Kholis

Submission date: 23-Dec-2021 06:18PM (UTC+1100)

Submission ID: 1735220843

File name: Penile_fracture_in_a_Peyronie_disease_-_October_2020.pdf (1,003.51K)

Word count: 3067


Character count: 16193

CASE REPORTS

Open Access

Penile fracture in a Peyronie's disease patient: a case report



Nur Hidayatullah¹, Khoiril Kholis², Muhammad Asykar Palinrungi^{2*} , Syakri Syahrir², Syarif Syarif² and Muhammad Faruk¹

Abstract

Background: Penile curvature in men with Peyronie's disease (PD)—caused by tunica anchoring plaques with loss of focal fiber elasticity—theoretically increases the risk of penile fracture during sexual activity. Penile fracture is the result of tearing of the tunica albuginea of one or both corpora cavernosa, usually during sexual intercourse, and is among the most serious urological emergencies. Generally, a patient presented to a surgical emergency within 48 h of injury can be handled successfully with minimum complications. Immediate surgical treatment is the current standard of care and has a relatively low risk of late complications.

Case presentation: We present a case of penile fracture in a male with a history of PD referred to the emergency department with severe pain. Clinical history assessment and physical examination revealed a penile fracture with underlying PD. He underwent emergency surgical exploration via subcoronal incision. Penile plication was not necessary for our case because the angulation of the penis was less than 15° after examination of artificial erection.

Conclusion: Penile fracture in a patient with underlying PD is a rare urological emergency that should be treated surgically with fracture repair as early as possible. Penile plication might be necessary in severe cases (angulation > 60°).

Keywords: Penile fracture, Tunica albuginea, Peyronie's disease, Case report

1 Background

The first penile rupture case was reported in 1957 by Fernstrom, who recommended surgical intervention after prolonged observation [1]. Penile fracture is among the most serious urological emergencies and is caused by a tear in the tunica albuginea and enclosed corpus cavernosum, which is often caused by anal intercourse, vigorous vaginal intercourse, masturbation, or any mechanical trauma that causes forcible bending of an erect penis [2]. Less common etiologies include reversing an erect penis during sleep, being kicked by animals, forced bending, a direct blow, gunshot wounds, or hastily removing or applying to clothing when the penis is erect [2]. Most

commonly, penile fracture involves one side of the corpora cavernosa. Penile fracture might also affect the corpora cavernosa, corpus spongiosum, or urethra [3].

Peyronie's disease (PD) is a fibrotic disorder of the tunica albuginea in the penis [4]. In 1743, PD was first described by Francois de la Peyronie as “rosary beads” of scar tissue, causing an upward curvature of the penis during erections [4–6]. Although the etiology of PD remains unclear, several theories have been proposed, and penile trauma is a widely accepted hypothesis [5]. This microvascular shear injury leads to inflammation, fibrin deposition, fibroblast activation, and results in the formation of a fibrous scar [4]. The management of evolving or early phase PD is conservative and nonoperative. Surgical management is only considered in severe cases after the fibrotic process has stabilized (approximately 12 months) [7].

Penile curvature in men with PD caused by tunica anchoring plaques with loss of focal fiber elasticity will

* Correspondence: apalinrungi@yahoo.com

² Division of Urology, Department of Surgery, Faculty of Medicine, Hasanuddin University, Perintis Kemerdekaan KM 11, Makassar 90245, Indonesia

Full list of author information is available at the end of the article



© The Author(s) 2020. This article is licensed under a Creative Commons Attribution 4.0 International License, which permits use, sharing, adaptation, distribution and reproduction in any medium or format, as long as you give appropriate credit to the original author(s) and the source, provide a link to the Creative Commons licence, and indicate if changes were made. The images or other third party material in this article are included in the article's Creative Commons licence, unless indicated otherwise in a credit line to the material. If material is not included in the article's Creative Commons licence and your intended use is not permitted by statutory regulation or exceeds the permitted use, you will need to obtain permission directly from the copyright holder. To view a copy of this licence, visit <http://creativecommons.org/licenses/by/4.0/>.

increase the risk of penile fracture during sexual activities due to reduced elasticity and erect penile orientation, which can cause trauma during vaginal penetration [7]. Here, we report the case of a patient with penile fracture and underlying PD.

2 Case presentation

A 47-year-old patient attended an ED with severe pain and had a history of penile injury following sexual intercourse close to 4 h ago. He provided a clear history of rough sexual intercourse, heard a cracking sound from his penis, and slippage of the penis out of the vagina followed by rapid detumescence. Three years previously, he had a PD with a chief complaint that his penis deviates toward the left with painful erection, but no erectile dysfunction. On examination, there was a plaque of 2 × 1 cm present along the left side of the shaft of the dorsal penis, just proximal to the glans. This plaque was hard in consistency, and when erect, the patient's penis had a 20° curvature, so we decided for nonsurgical management. Nowadays, on physical examination, the patient had normal vital signs. The penis was angulated to the left with edema and local hematoma formation (Fig. 1a, b). The tunica albuginea defect and plaque of PD was not palpable at the left side of the penis shaft, which might be the cause of the edema. Clinical history assessment and physical examination revealed a penile fracture with underlying PD.

Surgical exploration via subcoronal incision was performed three h after the patients were admitted to the hospital (Fig. 2a). After degloving the penis, it revealed a defect of around 2 × 1 cm over the left anterolateral aspect of tunica albuginea (Fig. 2b). The defect was

repaired, and hematoma tissue debrided (Fig. 2c). Subsequent artificial erection after intracavernous saline injection displayed lateral penile curvature less than 15°. So we assumed this patient did not require penile plication. Postoperatively, the patients were given antibiotics, analgesics, and sedatives to prevent erection. Postoperative outcome, the patient had satisfactory progress and was advised to have his first sexual intercourse at 2 months. At regular follow up of 6 months, the patients reported normal erection and sexual activities.

3 Discussion

PD is considered an acquired inflammatory condition, and this opinion is supported by histopathological examination that shows the existence of perivascular inflammatory processes in the loose connective tissue located between the tunica albuginea and penile erection tissue causing the formation of plaque [4, 7]. One hypothesis is that bleeding within the multilayered tunica albuginea of the corpus cavernosum leads to the infiltration of chronic inflammatory cells by increasing the rate of TGF-β1 (transformation of beta-growth factor-1), and the formation of fibrin tissue. Over time, with chronic inflammation, the fiber elasticity of the tunica albuginea disappears focally at the site of plaque formation, which causes penile curvature when erect [7].

Although penile fracture is rarely associated with PD, erect penis angulation can cause greater trauma with vaginal penetration and an increased risk of penile fracture [7]. In our patients at the time of surgery, we did not obtain fibrosis plaque on the left shaft penis. This could be because the penis fracture area was precisely the same place as the plaque from PD. It is estimated that PD is

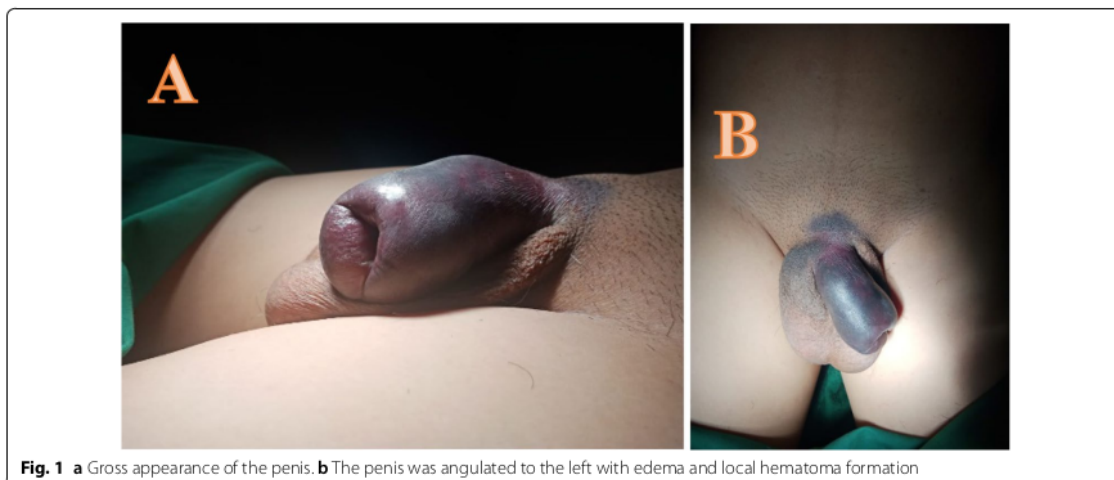
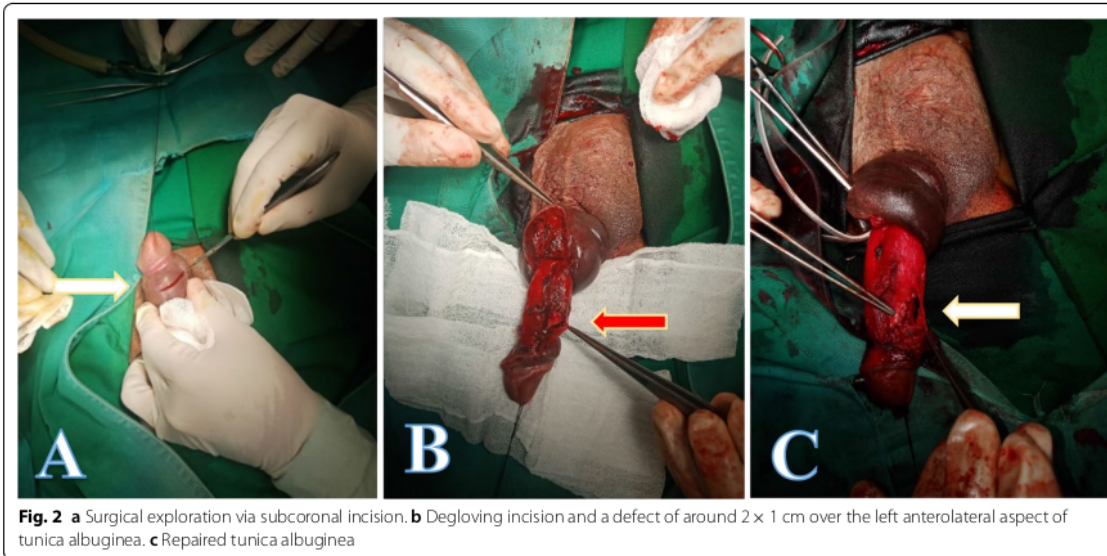


Fig. 1 a Gross appearance of the penis. b The penis was angulated to the left with edema and local hematoma formation



present in around 0.3–13.1% men around the world [5]. In German, Minor et al. [7] reported that the prevalence of the disease among men with a mean age of 57.4 years was 3.2%. A linear trend was observed for the prevalence of the disorder ranging from 1.5% for 30- to 39-year-old men to 6.5% for men > 70 years old [4].

Penile fracture is the tearing of the tunica albuginea from the corpus cavernosa [8]. The tunica albuginea is among the toughest of body fascias. (It is able to withstand rupture at pressures above 1500 mmHg.) The tunica albuginea measures 2 mm in a flaccid penis and becomes thinner (0.25–0.5 mm) during erection [9]. Rupture of the tunica albuginea is more likely when the penis erect because the tissue of the tunica albuginea is thinner and vulnerable to a sudden increase in the intracorporeal pressure. The corpus spongiosum and urethrae might also be affected. The tear is mostly unilateral and transverse [10]. However, it is well known that most patients have some unilateral damage to the corpus cavernosum [11, 12]. Only a small percentage have a urethral injury. In fact, in the most extensive series published on this subject, only 5 of 300 patients had evidence of urethral injury [13].

The etiology of penile fracture varies with the geographical area. In the Western hemisphere, sex is the majority cause of penile fracture cases [9, 14]. In Japan, it was reported that only 19% of penile fracture cases resulted from sexual intercourse, with a larger proportion caused by masturbation and rolling in bed when the penis was erect [15]. Meanwhile, in the Middle East and

North African countries, the most frequently reported cause is forced manipulation [1].

Kramer [16] reported a retrospective study of 16 patients with penile fractures undergoing surgery, and that there was an association between this clinical condition and sexual relations under stressful situations. Meanwhile, in another study in Saudi Arabia in 2014, it was found that heterosexual relationships were the most common cause (67%), with fewer cases resulting from penis manipulation (14%) and homosexual intercourse (10%). Woman on top was the most common heterosexual position resulting in penile fracture (50% cases), followed by “doggy style” (29% cases), and in four patients (10% cases), the cause was unclear [17]. El-Taher et al. [18] reported that 67% of cases were in the proximal shaft, and McAninch et al. reported that the distal third of the penile shaft is most often involved.

Penile fracture diagnoses are made based on history and clinical examination, as well as the classic triad of audible “cracking,” followed by rapid detumescence and intense pain. Although imaging might be necessary for better evaluation, it is often unnecessary [19]. A urethral injury should always be ruled out by asking about any voiding difficulty, history of blood per meatus or hematuria, and a retrograde urethrogram should promptly be requested to optimize treatment planning with simultaneous urethral repair during surgery [17, 20].

Ultrasonography (US) is often used for evaluation of suspected penile fractures [2] and PD [7], because it can identify the specific location of a tear in almost all patients. US can confirm the diagnosis of penile fracture

and determines the location of the plaque, thus guiding the specific location of the incision.

PD surgery management (penile plication) is typically done if the curvature is $>60^\circ$ [7]. In our patient, penis angulation was less than 15° upon induction of an artificial erection, so we did not perform penile plication.

Some previous studies have favored conservative treatment for traumatic rupture to the penis. However, because 10–30% of these patients experience coitus difficulties, penile deformities, and suboptimal erections, conservative management is now unpopular [16]. Cummings et al. (1998) reported that a delay of 24–48 h does not adversely impact the postoperative functioning of the penis [21]. Bozzini et al. show that delaying surgical intervention results in significant erectile dysfunction. Surgical treatment must be planned as soon as possible to avoid postoperative erectile dysfunction [1]. A multicenter study with a large sample in Europe in 2018 reported that delaying surgical intervention results in significant erectile dysfunction [1]. On the other hand, there is literature reporting that definitive therapy with excellent results is still possible after a sufficiently golden period of trauma, without increasing long-term complications [18, 22].

The most frequent postoperative complaints of penile fracture are erection dysfunction, penile curvature, pain with erection, and penile scarring [2, 9]. Meanwhile, for patient PD who underwent plication are penile shortening, discomfort at suturing location due to palpable suture knots, and pain with erection [4, 7]. For our patient, no complication occurred in surgical management, and there was no disturbance of sexual intercourse.

4 Conclusion

Penile fracture in a patient with underlying PD is a rare urological emergency that should be treated surgically with fracture repair as early as possible. Penile plication is also necessary in severe cases (angulation $>60^\circ$).

Abbreviations

Cm: centimeter; mm: millimeter; mmHg: millimeters of mercury; PD: Peyronie's disease; ED: emergency department; US: ultrasonography.

Acknowledgements

Not applicable.

Authors' contributions

KK, MAP, SS, SY, NH, and MF researched the literature and wrote the manuscript. KK, MAP, NH, and MF operated on the patient and had the idea for this case report. KK, MAP, SS, and SY checked the manuscript and made corrections. KK, MAP, SS, and SY provided the overall guidance and support. All authors read and approved the final manuscript.

Funding

Not applicable.

Availability of data and material

Not applicable.

Compliance with ethical standards

Ethics approval and consent to participate

Not applicable.

Consent for publication

Written informed consent was obtained from the patient for publication of this case report and accompanying images.

Competing interests

The authors declare that they have no competing interests.

Author details

¹ Department of Surgery, Faculty of Medicine, Hasanuddin University, Perintis Kemerdekaan KM 11, Makassar 90245, Indonesia. ² Division of Urology, Department of Surgery, Faculty of Medicine, Hasanuddin University, Perintis Kemerdekaan KM 11, Makassar 90245, Indonesia.

Received: 18 March 2020 Accepted: 14 July 2020

Published online: 02 October 2020

References

- Bozzini G, Albersen M, Otero JR et al (2018) Delaying surgical treatment of penile fracture results in poor functional outcomes: results from a large retrospective multicenter european study. *Eur Urol Focus* 4:106–110. <https://doi.org/10.1016/j.euf.2016.02.012>
- Mirzazadeh M, Fallahkarkan M, Hosseini J (2017) Penile fracture epidemiology, diagnosis and management in Iran: a narrative review. *Transl Androl Urol* 6:158–166. <https://doi.org/10.21037/tau.2016.12.03>
- Gupta N, Goyal P, Sharma K et al (2017) Penile fracture: role of ultrasound. *Transl Androl Urol* 6:580–584. <https://doi.org/10.21037/tau.2017.03.38>
- Smith JF, Walsh TJ, Lue TF (2008) Peyronie's disease: a critical appraisal of current diagnosis and treatment. *Int J Impot. Res* 20:445–459. <https://doi.org/10.1038/ijir.2008.30>
- Al-Thakafi S, Al-Hathal N (2016) Peyronie's disease: a literature review on epidemiology, genetics, pathophysiology, diagnosis and work-up. *Transl Androl Urol* 5:280–289. <https://doi.org/10.21037/tau.2016.04.05>
- Mirza M, Saria M, Mumtaz T (2006) Peyronie's disease. *J Ayub Med Coll Abbottabad* 18:66–67
- Minor TX, Brant WO, Rahman NU, Lue TF (2006) Approach to management of penile fracture in men with underlying Peyronie's disease. *Urology* 68:858–861. <https://doi.org/10.1016/j.urology.2006.05.022>
- Bali RS, Rashid A, Mushtaque M et al (2013) Penile fracture: experience from a third world country. *Adv Urol* 2013:1–4. <https://doi.org/10.1155/2013/708362>
- Galanakis I, Adamos K, Spyropoulos E, Mavrikos S (2018) Delayed successful surgical repair of penile fracture: a case report. *Curr Urol* 12:111–112. <https://doi.org/10.1159/000489428>
- Waseem M, Upadhyay R, Kapoor R, Agyare S (2013) Fracture of the penis: an atypical presentation. *Int J Emerg Med* 6:32. <https://doi.org/10.1186/1865-1380-6-32>
- Ishikawa T, Fujisawa M, Tamada H et al (2003) Fracture of the penis: nine cases with evaluation of reported cases in Japan. *Int J Urol* 10:257–260. <https://doi.org/10.1046/j.1442-2042.2003.00619.x>
- Atat R, Sfaxi M, Benslama M et al (2008) Fracture of the penis: management and long-term results of surgical treatment. experience in 300 cases. *J Trauma* 64:121–125. <https://doi.org/10.1097/TA.0b013e31803428b3>
- Naraynsingh V, Hariharan S, Goetz L, Dan D (2009) Late delayed repair of fractured penis. *J Androl* 31:231–233. <https://doi.org/10.2164/jandr.01.109.008268>
- Falcone M, Garaffa G, Castiglione F, Ralph DJ (2018) Current management of penile fracture: an up-to-date systematic review. *Sex Med Rev* 6:253–260. <https://doi.org/10.1016/j.jsxmr.2017.07.009>
- Jack GS, Garraway I, Reznichak R, Rajfer J (2004) Current treatment options for penile fractures. *Rev Urol* 6:114–120

- 4
16. Kramer AC (2011) Penile fracture seems more likely during sex under stressful situations. *J Sex Med* 8:3414–3417. <https://doi.org/10.1111/j.1743-6109.2011.02461.x>
 17. Agrawal SK, Morgan BE, Shafique M, Shazely M (1991) Experience with penile fractures in Saudi Arabia. *Br J Urol* 67:644–646. <https://doi.org/10.1111/j.1464-410x.1991.tb15232.x>
 18. El-Taher A, Abolella H, Sayed M, Gaafar A (2004) Management of penile fracture. *J Trauma* 56:1138–1140. <https://doi.org/10.1097/01.TA.0000033140.73750.14>
 19. Sawh SL, O'Leary MP, Ferreira MD et al (2008) Fractured penis: a review. *Int J Impot Res* 20:366–369. <https://doi.org/10.1038/ijir.2008.12>
 20. Koga S, Saito Y, Arakaki Y et al (1993) Sonography in fracture of the penis. *Br J Urol* 72:228–229. <https://doi.org/10.1111/j.1464-410x.1993.tb00693.x>
 21. Cummings JM, Parra RO, Boullier JA (1998) Delayed repair of penile fracture. *J Trauma Inj Infect Crit Care* 45:153–154. <https://doi.org/10.1097/00005373-199807000-00032>
 22. Nicolaisen GS, Melamud A, Williams RD, McAninch JW (1983) Rupture of the corpus cavernosum: surgical management. *J Urol* 130:917–919. [https://doi.org/10.1016/s0022-5347\(17\)51574-8](https://doi.org/10.1016/s0022-5347(17)51574-8)

Publisher's Note

Springer Nature remains neutral with regard to jurisdictional claims in published maps and institutional affiliations.

Submit your manuscript to a SpringerOpen® journal and benefit from:

- Convenient online submission
- Rigorous peer review
- Open access: articles freely available online
- High visibility within the field
- Retaining the copyright to your article

Submit your next manuscript at ► [springeropen.com](https://www.springeropen.com)

Penile fracture in a Peyronie disease - turnitin

ORIGINALITY REPORT

7%

SIMILARITY INDEX

5%

INTERNET SOURCES

5%

PUBLICATIONS

0%

STUDENT PAPERS

PRIMARY SOURCES

- 1 jurnal.unissula.ac.id 1%

Internet Source
- 2 Fabio Castiglione, David J. Ralph, Giulio Garaffa. "Chapter 14 The Management of Peyronie's Disease", Springer Science and Business Media LLC, 2018 1%

Publication
- 3 G.V.Soundra Pandyan, Ahmed Bakeet Zaharani, Mohammed Al Rashid. "Fracture Penis: An Analysis of 26 Cases", The Scientific World JOURNAL, 2006 1%

Publication
- 4 cshperspectives.cshlp.org 1%

Internet Source
- 5 Madhumita Parmar, John M. Masterson, Thomas A. Masterson. "The role of imaging in the diagnosis and management of Peyronie's disease", Current Opinion in Urology, 2020 1%

Publication
- 6 pagepressjournals.org 1%

Internet Source

7	www.hindawi.com Internet Source	<1 %
8	John P. Mulhall, Jonathan Schiff, Patricia Guhring. "An Analysis of the Natural History of Peyronie's Disease", The Journal of Urology, 2006 Publication	<1 %
9	experts.nebraska.edu Internet Source	<1 %
10	file.scirp.org Internet Source	<1 %
11	scholar.valpo.edu Internet Source	<1 %
12	www.cua.org Internet Source	<1 %
13	Matheus Roque, Sandro C. Esteves. "Effect of varicocele repair on sperm DNA fragmentation: a review", International Urology and Nephrology, 2018 Publication	<1 %
14	ajbm.net Internet Source	<1 %
15	www.consultant360.com Internet Source	<1 %
16	www.scirp.org Internet Source	<1 %

<1 %

17 zaguan.unizar.es
Internet Source

<1 %

18 revmedicina.sld.cu
Internet Source

<1 %

Exclude quotes Off

Exclude matches Off

Exclude bibliography Off

Penile fracture in a Peyronie disease - turnitin

GRADEMARK REPORT

FINAL GRADE

/0

GENERAL COMMENTS

Instructor

PAGE 1

PAGE 2

PAGE 3

PAGE 4

PAGE 5